

Efficacy and Safety of Simultaneous Application of HIFEM and Synchronized Radiofrequency for Abdominal Fat Reduction and Muscle Toning: A Multicenter Magnetic Resonance Imaging Evaluation Study

Carolyn Jacob, MD,* David Kent, MD,† and Omer Ibrahim, MD*

BACKGROUND Radiofrequency and high-Intensity Focused Electromagnetic (HIFEM) field procedure are well-known, stand-alone, body-shaping modalities, yet their simultaneous application has not been investigated.

OBJECTIVE The aim is to evaluate the efficacy of a novel device simultaneously delivering HIFEM and radiofrequency for subcutaneous fat reduction and muscle toning.

MATERIALS AND METHODS Forty-one subjects with an average age of 39.7 ± 11.5 years were recruited. The subjects received 3 abdominal treatments (one per week). Magnetic resonance imaging images of the treated area were evaluated at baseline and at 1-, 3-, and 6-month visits for changes in subcutaneous fat, muscle thickness, and abdominal separation (AS). Anthropometric data and digital photographs were collected. Subject satisfaction and therapy comfort were evaluated.

RESULTS The muscle mass increase peaked at 3 months, showing 26.1% thickening. The fat thickness reduction was most prominent at 3 months, showing a 30.8% reduction. The AS decreased by 18.8% at 3 months after treatment. The waist circumference reduced by 5.87 ± 3.64 cm at a 3-month follow-up. Six-month data showed maintenance of these outcomes. The treatment was considered as comfortable with high patient satisfaction.

CONCLUSION The analysis of magnetic resonance imaging images and waist measurements showed that the therapy combining HIFEM and radiofrequency is highly effective in reducing subcutaneous fat and muscle thickening.

The field of noninvasive body shaping is primarily represented by 2 types of devices.¹ The first type is focused on subcutaneous fat reduction through thermal stress, either heating or cooling, which induces damage to fat cells. These devices utilize cryolipolysis, radiofrequency (RF), focused ultrasound, or lasers to induce the thermal stress.²

The second approach in noninvasive body shaping is focused on muscular tissue. The first widely used device introduced only in 2018³ is based on high-Intensity Focused Electromagnetic (HIFEM) technology, which generates an alternating magnetic fields that induce electric current in the tissue, which stimulates motor neurons and triggers muscle contractions. The therapy was found to result in a significant thickening of muscle tissue while having an effect on subcutaneous adipose tissue as well.⁴⁻⁶

However, to achieve the total body shaping effect, that is, fat reduction and toned muscles, a combination of these 2 modalities would be optimal. This approach is common,

but it is time consuming for the patient and the practice because the devices can only be used consecutively. Therefore, a technology that simultaneously combines the muscle stimulation and fat reduction modalities would be highly beneficial.

The outcomes of recent research suggest that muscle stimulation and tissue heating could work in synergy and promote the effects on the muscles.⁷⁻⁹ Goto and colleagues¹⁰ showed that the simultaneous application of heat and mechanical stimulation to muscle induces significantly higher expression of heat shock proteins that play a crucial role in muscle hypertrophy by promoting muscle protein synthesis.¹¹ Similarly, both heat and mechanical stimuli can activate myosatellite cells—muscle-derived stem cells involved in myofiber development and renewal.¹²

Synergistic effects of the simultaneous application of heat and muscle stimulation could also manifest in the adipose tissue. Also, HIFEM-induced localized muscle workload increases the demand for energy and thus the fat metabolism.^{4,5} Heat itself increases lipolysis, and when sustained at temperatures of 42 to 45°C, adipocytes lose their cellular integrity and undergo apoptosis.¹³ Adipose tissue could thus be affected in 2 different ways, which may translate into boosting the treatment outcomes.

From the *Chicago Cosmetic Surgery and Dermatology, Chicago, Illinois;† Skin Care Physicians of Georgia, Macon, Georgia

The authors have indicated no significant interest with commercial supporters.

Address correspondence and reprint requests to: Carolyn Jacob, MD, 515N State St Ste 900, Chicago, IL 60654, or e-mail: cjacob@chicagodermatology.com

<http://dx.doi.org/10.1097/DSS.0000000000003086>

For such purpose, a novel technology allowing simultaneous application of HIFEM and RF in a synchronized manner has been developed. The technology overcomes the interferences between the 2 modalities by a unique design of synchronized RF electrodes that prevent the creation of eddy currents. It is hypothesized that the technology for the simultaneous application of HIFEM and synchronized RF should result in synergistic effects in both muscle and adipose tissues. Therefore, this study aims to investigate the efficacy and safety of such novel technology for abdominal body shaping.

Materials and Methods

Study Population

Forty-one subjects (17 men and 24 women) interested in the noninvasive aesthetic improvement of abdomen participated in this prospective, multicenter, open-label, single-arm study. The inclusion criteria included adult subjects of any gender with a body mass index (BMI) lower than 35 kg/m². The study's exclusion criteria were pregnancy, postpartum period, breastfeeding, injury in the treatment area, or any other medical conditions that contraindicate the application of electromagnetic fields and RF, such as cardiovascular disease, malignant tumor, metal, or electronic implants. Subjects who met the inclusion criteria and were recruited as study participants were, on average, 39.7 ± 11.5 years old and had a BMI of 26.56 ± 3.73 kg/m² at the beginning of the study.

Study Design

The study design and the treatment protocol were approved by the Institutional Review Board and followed the ethical guidelines of the 1975 Declaration of Helsinki.

Each subject received three 30-minute treatments on the abdomen with the device simultaneously delivering HIFEM and RF energies through a single applicator (Emsculpt NEO, BTL Industries, Inc., Boston, MA). The treatments were administered once a week. All of the patients were instructed to maintain their daily routine and not to change their lifestyle. Before the treatment, each subject received detailed instructions about the study and signed informed consent.

During the treatments, no anesthesia was required. Patients were positioned in a supine position with the applicators centered over the umbilicus. In case the patients' constitution allowed, 2 applicators were used bilaterally, centered above both lateral sides of the rectus abdominis. Applicators were affixed with a fixation belt to avoid the possibility of movement during the treatment. Each treatment lasted for 30 minutes, starting with the HIFEM intensity set to 0%, increasing it to the maximum tolerable level. The RF intensity was set to 100% since the beginning of the procedure. Patients were regularly asked about the therapy comfort during the whole treatment time, and the energy settings were adjusted accordingly. Digital photographs of the treatment area, waist circumference measurements, weight and height records, and magnetic resonance imaging (MRI) images of the treatment area were collected at baseline and at 1-, 3-, and 6-month follow-up visits.

Data Collection and Evaluation

Magnetic resonance imaging was used as the primary evaluation modality for assessing the treatment effects on muscle and adipose tissue thickness and abdominal separation (AS) width. The scanning area was defined by T12 and S1 vertebrae. The images were acquired by the FIESTA and FSPRG sequences (Matrix: 380 × 380, ST: 5 mm, Spacing: 1 mm) in a transverse plane. The muscle and fat thickness measurements were performed supraumbilically and infraumbilically, approximately 2 inches (5 cm) above and below the umbilicus. The AS was measured at the same MRI slices as a perpendicular distance between the 2 parallel pairs of rectus abdominis muscle. Data collection was done at baseline and at 1-, 3-, and 6-month follow-ups.

The patient's satisfaction with the treatment results was assessed using the Satisfaction Questionnaire with a 5-point Likert scale after the last treatment and each follow-up visit. The therapy comfort was evaluated using 10-point visual analogue scale (VAS) after each treatment session.

All data were statistically analyzed using repeated-measures analysis of variance, paired, and 2-sample *t*-test. Analyses showing *p*-values of <.05 were considered as significant.

Results

Forty patients completed the entire treatment procedure and attended the MRI screening at 1-month follow-up. One subject withdrew from the study before completing the whole procedure. Twenty-nine patients attended the 3-month follow-up visit, and 20 patients participated at the 6-month follow-up visit, including the MRI screening. The dropout rate seen at the MRI follow-up visits was considerably affected by the outbreak of COVID-19, which did not allow the patients to attend the visits in person. Therefore, 4 of these patients attended the 3- and 6-month follow-up visits virtually, where they were asked to report any adverse events, satisfaction with results, weight, and waist circumference measurements. These patients did not undergo MRI screening due to the restrictive measures.

Magnetic Resonance Imaging Evaluation

Subcutaneous Adipose Tissue

Evaluation of 1-month scans showed an average fat reduction across the abdomen by 24.4%. The patients lost 23.6% on average (−6.61 ± 2.9 mm) infraumbilically and 25.3% on average (−5.9 ± 2.7 mm) supraumbilically. The results were fairly consistent; although only 2 patients showed a reduction lower than 5%, 37 patients showed a reduction higher than 15%, and 33 patients showed a reduction higher than 20%.

At 3 months, the results further improved significantly (*n* = 29; *p* < .05) in comparison to 1 month as the patients lost, on average, 30.8% of fat since the baseline visit. Supraumbilically, the patients lost 7.3 ± 3.3 mm (31.9%) on average and 7.9 ± 2.5 mm (29.7%) infraumbilically. At 3-month follow-up, there were no nonresponders with

TABLE 1. Detailed Result Summary of MRI Measurements

Measurement	Location	Baseline (N = 40)	1M FU (N = 40)	3M FU (N = 29)	6 M FU (N = 20)
Fat thickness	Infraumbilicus	28.6 ± 11.8 mm	22.0 ± 10.0 (−23.6%)	19.9 ± 8.1 (−29.7%)	21.0 ± 8.9 (29.1%)
	Supraumbilicus	24.2 ± 11.7 mm	18.3 ± 9.8 (−25.3%)	16.4 ± 8.5 (−31.9%)	17.8 ± 8.2 (27.5%)
Muscle thickness	Infraumbilicus	9.2 ± 2.3 mm	11.2 ± 2.5 (+22.0%)	11.6 ± 3.0 (+24.7%)	11.2 ± 2.2 (26.4%)
	Supraumbilicus	8.7 ± 2.3 mm	10.7 ± 2.5 (+24.9%)	11.1 ± 2.7 (+27.4%)	10.6 ± 2.0 (24.1%)
Abd. separation	Infraumbilicus	16.6 ± 6.3 mm	13.7 ± 5.6 (−17.8%)	12.9 ± 4.9 (−19.6%)	12.4 ± 5.3 (20.0%)
	Supraumbilicus	21.4 ± 6.3 mm	18.1 ± 5.5 (−15.8%)	17.4 ± 5.2 (−18.8%)	17.8 ± 5.3 (19.6%)

MRI, magnetic resonance imaging; FU, follow-up; M, month.

reduction lower than 5%. Twenty-eight out of the 29 patients showed a reduction higher than 20%, and in 23 patients, the reduction exceeded 25%. All changes were statistically significant ($p < .05$).

In the group of 20 subjects who underwent the MRI screening at 6-month follow-up showed that the improvement achieved at 3 months (30.8%) was mostly preserved with the average reduction of 28.3% in comparison to baseline, yet showing a statistically insignificant ($p > .05$) decreasing trend. At 6 months, 7 out of the 20 subjects showed a decrease in the improvement of more than 5% when compared with the results at 3-month follow-up.

Table 1 shows a detailed result summary. An example of a patient MRI scan can be seen in Figure 1.

Muscular Tissue

The thickness of the rectus abdominis was increased by 23.5% on average at 1-month posttreatment. At infraumbilical slices, the average increase was equal to 1.9 ± 0.7 mm in absolute values corresponding to an average 22.0% increase in the thickness. Supraumbilical slices showed thickening by 2.0 ± 0.8 mm, corresponding to 24.9% increase on average. There were no nonresponding patients, and in 32 out of 40 patients, the thickness of rectus abdominis increased by more than 18%.

Similar to the fat tissue, the results in muscles continued to improve at 3-month follow-up. The average increase in muscle thickness was 26.1% ($+2.3 \pm 0.8$ mm), whereas

24.8% thickening was seen infraumbilically and 27.4% supraumbilically. All changes were statistically significant ($p < .05$).

At 6 months, the MRI scans of 20 subjects showed that the results of these patients were maintained. Data of this group showed a 25.8% thickening at 3 months, which was then maintained at 25.3% at 6-month follow-up visit.

Table 1 shows a detailed result summary.

Abdominal Separation

The width of AS reduced significantly ($p < .05$) at both the supraumbilical and infraumbilical slices in all of the examined subjects. Supraumbilically, the average width of AS was reduced by 16.0% at 1-month follow-up and by 17.6% at 3-month follow-up. Infraumbilically, the AS reduced by 16.4% at 1 month and by 19.2% reduction at 3-month follow-up (detailed results are given in Table 1).

According to the supraumbilical slices, 8 out of the 40 patients experienced diastasis recti at baseline. It is a condition when the gap between the 2 sides of rectus abdominis muscles exceeds 27 mm.¹⁴ In this group, the AS was reduced by 4.8 ± 1.7 from 30.1 ± 2.1 mm at baseline to 25.4 ± 2.0 mm at 1-month follow-up. In 6 patients, the condition was fully corrected at 1-month follow-up.

At 6 months, the overall reduction in AS was 19.8%. Of the 20 subjects examined at 6 months, 5 experienced diastasis recti at baseline. At 6 months, 4 subjects were fully without diastasis recti, and only a single subject exceeded the 27-mm range, yet this subject showed a prominent reduction as at baseline: the AS was 33.4 mm, whereas the 6-month measurements showed an AS of 27.5 mm.

Patient Satisfaction and Treatment Comfort

The patients found the treatments comfortable with a score of 2.3 ± 1.8 on a 10 point VAS (0 = no discomfort; 10 = unbearable pain). By the end of the first treatment, most patients reached 100% intensity of the HIFEM field. The intensity of RF was adjusted in most patients based on their individual perception of the heat.

The satisfaction questionnaire's analysis revealed high patient satisfaction as 91% of patients reported satisfaction

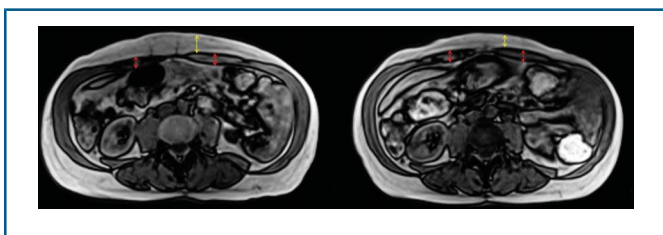


Figure 1. Magnetic resonance images illustrating the changes in the treated area. Supraumbilical slices taken at baseline (left) and at 3-month follow-up (right) of a 62-year-old woman. Individual patient's improvement reached −45.6% in fat reduction and +14.6% in muscle thickness, respectively. Fat tissue is marked with yellow arrows, rectus abdominis muscle by red color.

with the treatment results at 3-month posttreatment. Ninety-four percent of patients reported improved appearance of the abdomen, and 91% reported improvement in both muscle and fat.

No severe adverse events or side effects of the treatment were reported. In all patients, the treatment was associated with mild erythema following treatment and dissipated rapidly, and some patients experienced mild muscle soreness on the day after treatment.

Waist Circumference and Weight Measurements

The waist circumference was reduced by 3.3 ± 3.1 cm on average at 1-month follow-up visit. At 3 months, the average circumferential reduction was 5.9 ± 3.6 cm. The patients attending 6-month visit showed a 6.7 ± 3.5 cm reduction in waist circumference. The weight did not show any major fluctuations between any of the time points. Digital photographs showed notable improvement. Figure 2 provides an example of patients' result.

Discussion

The treatments with a novel device that delivers HIFEM and synchronized RF energies simultaneously resulted in a statistically significant increase in muscle mass, reduction in the fat layer thickness, and reduction in AS. The results in all 3 measured parameters showed improvement up to 3 months at which time the results peaked. The MRI observations were accompanied by reduced waist circumference and improved body image in digital photographs. At 6 months, no further improvements were observed, but the results seen at a 3-month follow-up were maintained in the majority of the patients. Although the results at 6 months are still highly above baseline values, the patients may benefit from additional maintenance treatments to reverse the declining tendency and to prolong the longevity of achieved outcomes.

The study did not include control groups that would receive HIFEM-only and RF-only treatments. However,

several studies were published in the past solely for these modalities, allowing for comparison with the outcomes of this study. Studies on the abdominal application of HIFEM did show an average subcutaneous fat reduction^{6,15,16} of 19.6% (17.5%–23.3%), average muscle thickening^{6,15} of 15.1% (14.8%–15.4%), and an average reduction in AS^{6,15} by 9.95%. When compared with our results with the simultaneous application of HIFEM and RF, it appears that the synergy of the 2 energies has a truly high impact on the final outcome because it yields more than 50% higher improvement in all 3 measured parameters.

Studies^{13,17–21} investigating the application of RF systems for subcutaneous fat reduction report a fat thickness reduction ranging from 4.9% to 29.0% with a weighted average of 14.58%. Nevertheless, the comparison with other RF studies may not be as precise because the studies investigate various systems of different frequencies and other properties. However, they do provide an overview of the expected patient results of treatment with this modality.

Our results are in agreement with the fact that combination treatments in general are considered more effective than stand-alone treatments. Study by Kilmer and colleagues²² found that consecutive treatments of cryolipolysis and electromagnetic technology result in better subjective perception of the treatment outcomes than stand-alone treatments as seen in patient satisfaction or photographic evaluation. The study also reported higher waist circumference reduction after the combined treatments of 1.5 cm. Considering this result, it can be seen that simultaneous application of HIFEM and RF is more effective in waist reduction (–5.9 cm) than consecutive application of cryolipolysis and electromagnetic technology (–1.5 cm).

Although this is a first MRI study investigating the effects of simultaneous application and further research is necessary to validate these findings, the results seem to exceed the outcomes of individual HIFEM and RF treatment. Regarding muscle tissue, it is assumed that the synergistic effect could be attributed to the physiologic nature of muscle synthesis regulating molecules, such as heat shock proteins¹⁰ and satellite cells,¹² which concentrations and state can be altered by both mechanical stimulation and heat.

One of the study limitations is the high dropout rate at the 3- and 6-month follow-ups, mainly attributed to the outbreak of COVID-19, as attending follow-up visits would pose risks of infection to the patients. However, 29 patients out of 40 at a 3-month visit represent 72.5% of the initial population and still provide valuable data about the treatment outcomes. The lack of a control group can also be considered as a limitation and should be implemented in future studies.

Conclusion

Simultaneous application of HIFEM and RF is safe and effective for muscle toning and fat reduction. The results suggest this application as more effective for fat reduction and muscle increase than using these energies stand-alone or

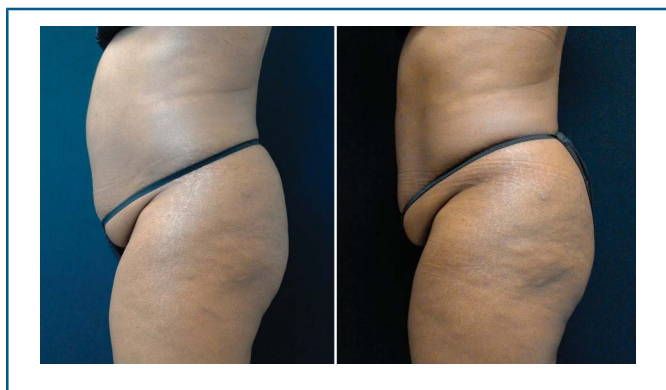

Figure 2. Digital photographs taken at (left to right) baseline and at 1-month posttreatment. At 6 months, the 50-year-old woman showed 24.8% fat reduction, 23.7% muscle thickening, and 8-cm waist circumference reduction.

consecutively. Further studies are required to support these outcomes.

References

1. Mazzoni D, Lin MJ, Dubin DP, Khorasani H. Review of non-invasive body contouring devices for fat reduction, skin tightening and muscle definition. *Australas J Dermatol* 2019;60:278–83.
2. Kennedy J, Verne S, Griffith R, Falto-Aizpurua L, et al. Non-invasive subcutaneous fat reduction: a review. *J Eur Acad Dermatol Venereol* 2015;29:1679–88.
3. Hoffmann K, Soemantri S, Hoffmann K, Hoffmann KKP. Body shaping with high-intensity focused electromagnetic technology. *J Für Ästhetische Chir* 2020;13:64–9.
4. Weiss RA, Bernardy J. Induction of fat apoptosis by a non-thermal device: mechanism of action of non-invasive high-intensity electromagnetic technology in a porcine model. *Lasers Surg Med* 2019;51:47–53.
5. Halaas Y, Bernardy J. Mechanism of nonthermal induction of apoptosis by high-intensity focused electromagnetic procedure: biochemical investigation in a porcine model. *J Cosmet Dermatol* 2020;19:605–11.
6. Kinney BM, Lozanova P. High intensity focused electromagnetic therapy evaluated by magnetic resonance imaging: safety and efficacy study of a dual tissue effect based non-invasive abdominal body shaping: MRI evaluation of electromagnetic therapy. *Lasers Surg Med* 2019;51:40–6.
7. Kakigi R, Naito H, Ogura Y, Kobayashi H, et al. Heat stress enhances mTOR signaling after resistance exercise in human skeletal muscle. *J Physiol Sci* 2011;61:131–40.
8. Kobayashi T, Goto K, Kojima A, Akema T, et al. Possible role of calcineurin in heating-related increase of rat muscle mass. *Biochem Biophys Res Commun* 2005;331:1301–9.
9. Uehara K, Goto K, Kobayashi T, Kojima A, et al. Heat-stress enhances proliferative potential in rat soleus muscle. *Jpn J Physiol* 2004;54:263–71.
10. Goto K, Okuyama R, Sugiyama H, Honda M, et al. Effects of heat stress and mechanical stretch on protein expression in cultured skeletal muscle cells. *Pflugers Arch* 2003;447:247–53.
11. Yoshihara T, Naito H, Kakigi R, Ichinoseki-Sekine N, et al. Heat stress activates the Akt/mTOR signalling pathway in rat skeletal muscle. *Acta Physiol* 2013;207:416–26.
12. Halevy O, Krispin A, Leshem Y, McMurtry JP, et al. Early-age heat exposure affects skeletal muscle satellite cell proliferation and differentiation in chicks. *Am J Physiol Regul Integr Comp Physiol* 2001;281:R302–309.
13. Adatto MA, Adatto-Neilson RM, Morren G. Reduction in adipose tissue volume using a new high-power radiofrequency technology combined with infrared light and mechanical manipulation for body contouring. *Lasers Med Sci* 2014;29:1627–31.
14. da Mota PGF, Pascoal AGBA, Carita AIAD, Bø K. Prevalence and risk factors of diastasis recti abdominis from late pregnancy to 6 months postpartum, and relationship with lumbo-pelvic pain. *Man Ther* 2015;20:200–5.
15. Kent DE, Jacob CI. Simultaneous changes in abdominal adipose and muscle tissues following treatments by high-intensity focused electromagnetic (HIFEM) technology-based device: computed tomography evaluation. *J Drugs Dermatol* 2019;18:1098–102.
16. Katz B, Bard R, Goldfarb R, Shiloh A, et al. Ultrasound assessment of subcutaneous abdominal fat thickness after treatments with a high-intensity focused electromagnetic field device: a multicenter study. *Dermatol Surg* 2019;45:1542–8.
17. Boisnic S, Divaris M, Nelson AA, Gharavi NM, et al. A clinical and biological evaluation of a novel, noninvasive radiofrequency device for the long-term reduction of adipose tissue: a clinical and biological evaluation of a novel. *Lasers Surg Med* 2014;46:94–103.
18. Hayre N, Palm M, Jenkin P. A clinical evaluation of a next generation, non-invasive, selective radiofrequency, hands-free, body-shaping device. *J Drugs Dermatol* 2016;15:5.
19. Wanitphakdeedecha R, Sathaworawong A, Manuskiatti W, Sadick NS. Efficacy of multipolar radiofrequency with pulsed magnetic field therapy for the treatment of abdominal cellulite. *J Cosmet Laser Ther* 2017;19:205–9.
20. Chang SL, Huang YL, Lee MC, Chang CH, et al. Combination therapy of focused ultrasound and radio-frequency for noninvasive body contouring in Asians with MRI photographic documentation. *Lasers Med Sci* 2014;29:165–72.
21. Manuskiatti W, Wachirakaphan C, Lektrakul N, Varothai S. Circumference reduction and cellulite treatment with a TriPollar radio-frequency device: a pilot study. *J Eur Acad Dermatol Venereol* 2009;23:820–7.
22. Kilmer SL, Cox SE, Zelickson BD, Bachelor EP, et al. Feasibility study of electromagnetic muscle stimulation and cryolipolysis for abdominal contouring. *Dermatol Surg* 2020;46:S14–21.